

# THE PROXIMAL HAMSTRING FOOTPRINT: AN ANATOMIC MAPPING STUDY

Michael Gerhardt MD, Timothy Neuschwander MD, Michael Benke MD

Santa Monica Orthopaedic and Sports Medicine Group, Institute for Sports Sciences, Cedars-Sinai Medical Foundation

## Purpose

The purpose of this study is to define the topographic anatomy of the footprint of the hamstrings origin on the ischium

## Introduction

Avulsion of the hamstrings tendon origin off the ischium is becoming a commonly recognized and treated athletic injury. Multiple case series detail excellent outcomes and near full recovery of strength after surgical repair. However, there is very little literature on the topographic anatomy of the region as it pertains to repair of the tendons, especially regarding the location on the ischium to which the avulsed hamstrings tendons are repaired. The most common post-operative complaint, pain with sitting, was reported as high as 61% in a recent series. This complaint could be due to non-anatomic repair of the avulsion to the ischial tuberosity rather than to the anatomic footprint; although no studies describe complications from a nonanatomic repair, several studies describe repairing the common hamstrings tendon to the ischial tuberosity. There is a simple technique for defining ligament and tendon insertions on bone using CT imaging and radio-opaque paint. This technique results in a 3D digital model where the tendon footprint topography can be described.

## Materials and Methods

Dissection of the hamstrings origin in 6 cadaveric pelvises was performed (FIG.1). The hamstring origin was isolated with sharp dissection, and it was noted whether the semimembranosus had a separate attachment, or whether there was one confluent tendon attached at the footprint (FIG 2). The common hamstrings tendon was then sharply dissected from the ischium and the footprint was outlined with surgical marker followed by radio-opaque paint (FIG 3). Paint was prepared by mixing 0.25g Daler-Rowney Acrylic Artists Ink Scarlet #567 (Bracknell, England) per gram of EZ-HD 98% v/w Barium Sulfate (Lake Success, NY). The paint was then applied to the area of the footprint and the specimen underwent a 0.5mm slice CT scan of the pelvis with 3D reconstructions (FIG 4). Vitrea (Vital Images, Minnetonka, MN) software was used to determine the surface area of the ligament footprint as well as the distance from the ischial tuberosity to the center of the footprint. The thickness of the bone underlying the footprint was measured. Data are presented as means  $\pm$  SE.

Figure 1: Outline of the footprint with surgical marker. The sciatic nerve is just to the right of the footprint.

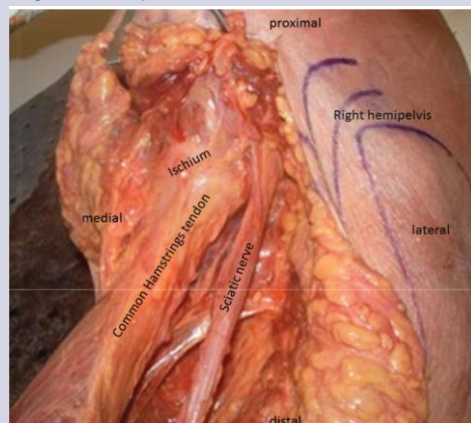


Figure 2: Detached common hamstrings tendon without a separation between the long head biceps/semiotendinosus and semimembranosus footprints.

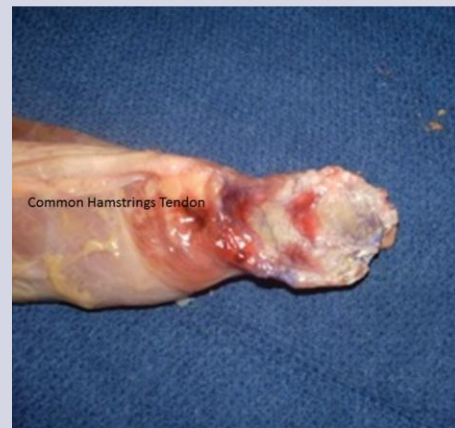

Figure 4: 3D reconstruction of a right hemi-pelvis with the surface area of the hamstrings footprint outlined. The reconstruction is pictured overlying the anatomic specimen.

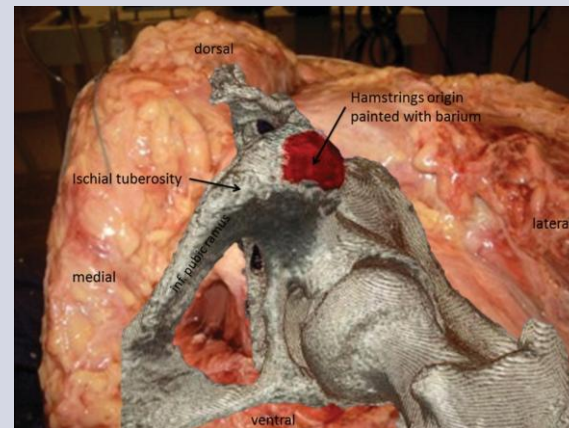


Figure 6: Average distance from the tip of the ischial tuberosity to the center of the hamstrings footprint measured 3.73 $\pm$ 0.22cm.

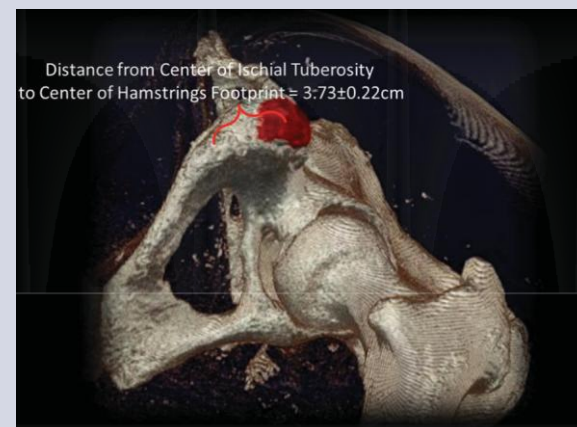


Figure 3: Application of radio-opaque paint to the footprint.

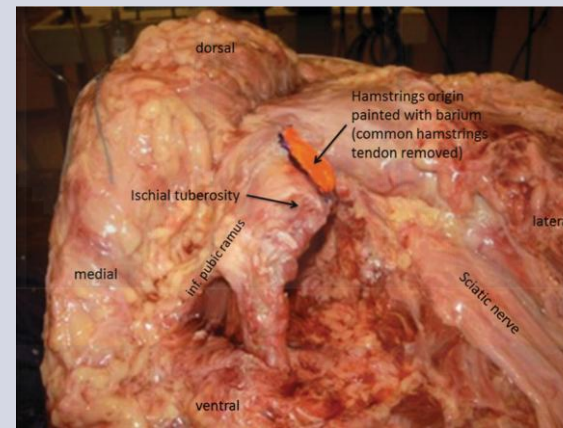
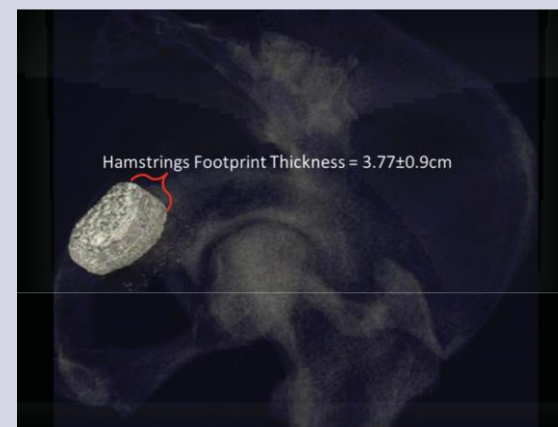


Figure 5: Average surface area of the of the hamstrings footprint measured 10.19 $\pm$ 0.75cm<sup>2</sup>.

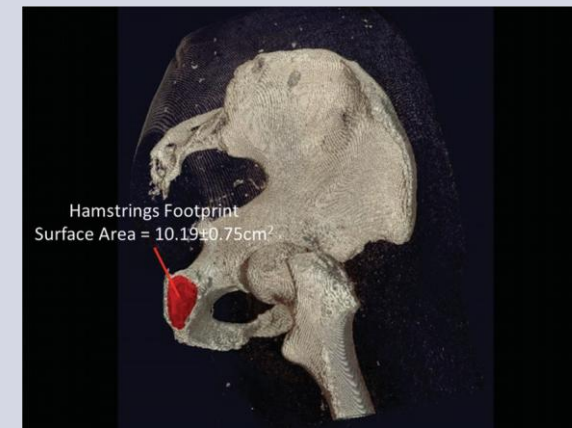

Figure 7: Average thickness of the bony footprint was 3.77 $\pm$ 0.9cm.



## Results

Five of six specimens had a common hamstrings tendon, while one had a separate attachment for the semimembranosus. The semimembranosus joined the common hamstrings tendon 2.33 $\pm$ 0.61cm distal to the footprint. The average surface area of the hamstrings footprint measured 10.19 $\pm$ 0.75cm<sup>2</sup> (FIG 5). The distance from the tip of the ischial tuberosity to the center of the hamstrings footprint measured 3.73 $\pm$ 0.22cm (FIG 6). The average thickness of the bone deep to the footprint was 3.77 $\pm$ 0.9cm (FIG 7).

## Discussion

The common hamstrings tendon originates on a facet approximately 4cm lateral to the tip of the ischial tuberosity. Its surface area is quite large, approximately 10cm<sup>2</sup>. The long head biceps/semiotendinosus and semimembranosus formed a common tendon more than 2cm from the bony footprint in 5/6 specimens, with one specimen having separate footprints. The bony hamstrings facet is sufficiently thick that perforation of the far cortex with commonly-made suture anchors is unlikely. Thus, using suture anchor fixation is a safe method of reattachment.

To our knowledge, the only previous cadaveric study to measure the footprint of the hamstrings origin is by Miller et al. While the authors do not specifically discuss surface area of the footprint, their figures demonstrate it to be slightly more than 3cm in length by about 2.9 cm in width, which would result in a surface area of about 7cm<sup>2</sup>. A 3-dimensional topographical measurement of surface area will be greater than a 2-dimensional one since it takes into account the "peaks and valleys" as well as curvature of the bone. Thus, we feel our surface area average of 10cm<sup>2</sup> is not in conflict with currently published studies. Previous studies discuss the distinction between the long head biceps/semiotendinosus and semimembranosus footprints on the ischial tuberosity. This was only seen in 1/6 of our cadaveric specimens; we were surprised to find the majority of our specimens semimembranosus joining the common tendon a little over 2 cm distal to the footprint. As such, we chose to report on the location of the entire footprint rather than artificially split the common tendon down to the footprint. Pain with sitting after proximal hamstrings repair, a common complication, could be due to non-anatomic reattachment of the common hamstrings tendon to the ischial tuberosity rather than to the anatomic footprint, which is actually 3-4cm proximal to the ischial tuberosity

## Conclusion

This study provides a topographical description of the origin of the hamstrings footprint.

**Clinical Relevance:** Our data will assist surgeons in performing anatomic repair of proximal hamstrings avulsions.

## References

1. Cohen SB, Bradley JP. Acute proximal hamstring rupture. *J Am Acad Orthop Surg.* 2007 Jun;15(6):350-5.
2. Birmingham P, Muller M, Wickiewicz T, Cavanaugh J, Rodeo S, Warren R. Functional outcome after repair of proximal hamstring avulsions. *J Bone Joint Surg Am.* 2011 Oct 5;93(19):1819-28.
3. Cohen SB, Rangavajjala A, Vyas D, Bradley JP. Functional results and outcomes after repair of proximal hamstring avulsions. *Am J Sports Med.* 2012 Sep;40(9):2092-8.
4. Salley PI, Ballard G, Hamersly S, Schrader M. Subjective and functional outcomes following surgical repair of complete ruptures of the proximal hamstring complex. *Orthopedics.* 2008 Nov;31(11):1092.
5. Miller SL, Webb GR. The proximal origin of the hamstrings and surrounding anatomy encountered during repair. *Surgical technique. J Bone Joint Surg Am.* 2008 Mar;90 Suppl 2 Pt 1:108-16.